

Treatment of Moderate to Severe Acne and Scars With a 650-Microsecond 1064-nm Laser and Isotretinoin

Michael H. Gold MD,^a Natalia E. Manturova MD PHD,^b Larisa S. Kruglova MD PHD,^c
Evgeniya V. Ikonnikova MD^c

^aGold Skin Care Center, Nashville, TN

^bCosmetology and Cellular Technologies, The Pirogov Russian National Research Medical University, Moscow, Russia

^cCentral State Medical Academy of the Administrative Department of President of the Russian Federation, Moscow, Russia

ABSTRACT

Background: Laser procedures for acne and acne scars have traditionally been postponed for at least 6 to 8 months after the end of systemic isotretinoin therapy. Lower dosages with more modern laser devices having unique energy parameters of high power in microsecond pulse durations have made it possible to administer laser therapy during or shortly after completion of isotretinoin therapy, thus reducing the risk of side effects of isotretinoin.

Methods: Patients with moderate to severe facial acne (n=46) and atrophic scars enrolled in a 6-month study. Genetic analysis of patients revealed the presence of polymorphisms of genes Col1A2, MMP3, ESR1, MMP1, and MMP7, which can lead to scar formation. Patients underwent low-dosage isotretinoin therapy (0.2-0.3 mg/kg/day) in combination with facial laser treatment using a 650-microsecond, 1064-nm Nd:YAG laser. Acne severity was graded using the Investigators Global Assessment (IGA) scale and quality of life was evaluated by the Dermatology Life Quality Index (DLQI).

Results: IGA parameters decreased from 1.8 ± 0.2 (mean \pm SD) initially to 0.5 ± 0.4 at the end of the study, a 72.3% reduction which was significant ($P < 0.01$). The DLQI index decreased from 10.1 ± 1.3 initially to 2.8 ± 1.2 , a 72.3%, a significant reduction ($P < 0.01$). Inflammatory elements resolved without scarring. Laser treatment was well tolerated and improvement in pre-existing scars was noticeable.

Conclusions: The 650-microsecond, 1064-nm laser in combination with low-dose isotretinoin is safe and effective in patients with acne complicated by atrophic scars and genetically prone to post-acne scarring.

J Drugs Dermatol. 2020;19(6):646-651. doi:10.36849/JDD.2020.5108

INTRODUCTION

Tradition holds that laser procedures to treat acne vulgaris should be postponed at least 6 to 8 months after the end of systemic therapy with isotretinoin. This is based on data suggesting that dermabrasion or laser therapy during isotretinoin treatment may induce keloid formation or delay the repair of skin integuments (ie, skin scar tissue).¹⁻⁷ The validity of this practice has recently been questioned.⁸⁻¹² In their consensus recommendations, Spring and colleagues¹⁰ reported insufficient evidence that physicians should delay manual dermabrasion, cutaneous surgery, superficial chemical peels, laser hair removal, and fractional ablative and nonablative laser procedures in patients receiving or recently completing therapy with isotretinoin. The authors did not, however, recommend mechanical dermabrasion and fully ablative laser therapy while patients underwent systemic isotretinoin treatment.

Two months later the American Society of Dermatologic Surgery reported its consensus recommendations regarding the safety of lasers, dermabrasion, chemical peels, energy devices, and skin surgery during and after isotretinoin use.¹¹ The Task Force concluded that evidence was lacking that physicians should delay procedures with chemical peels and nonablative lasers (ie, hair removal lasers and lights, vascular lasers, fractional devices) in patients currently or recently exposed to isotretinoin, and that superficial and focal dermabrasion, when performed by a well-trained professional, may also be safe.

Mysore and colleagues,¹² after reviewing published studies, reported that evidence for avoiding a variety of procedures (fractional CO₂ resurfacing, fractional Nd:YAG laser, fractional infrared lasers, laser hair removal, microdermabrasion using

aluminum crystals, microneedling [with and without radio-frequency], and cold steel surgeries) in patients undergoing isotretinoin therapy was poor or limited. The authors suggested that, instead of avoiding these procedures, physicians perform a test procedure to establish safety in selected patients taking isotretinoin.

The present study explores the efficacy and safety of using a 650-microsecond, 1064-nm Nd:YAG laser (LightPod Neo Elite, Aerolase Corp., Tarrytown, NY) in combination with low-dose isotretinoin for the treatment of acne and acne scars.

METHODS

Patients

Female (n=28) and male (n=18) patients, aged 18 to 30 years and skin types I through III enrolled in the 6-month study. All patients had moderate to severe facial acne (up to 20 papulopustular elements) complicated by atrophic scars. Genetic analysis of all patients revealed the presence of polymorphisms of ESR1, Col1A2, MMP1, MMP3, and MMP7 genes, known to be associated with the development of scars. The latter inclusion criterion is based on recent studies^{13,14} suggesting the existence of genetic predictors for the formation of atrophic post-acne scars. The ESR1 gene encodes an estrogen receptor, a transcription factor for hormone binding, DNA binding, and activation of transcription.¹⁵ The Col1A2 gene encodes the pro-alpha2 chain of type I collagen.¹⁶ The MMP genes encode the matrix metalloproteases, proteins involved in normal physiological processes (eg, tissue remodeling) and disease processes. The MMP1 gene encodes a protease that breaks down types I, II, and III interstitial collagens.¹⁷ The MMP3 gene encodes an enzyme that degrades fibronectin, laminin, collagens III, IV, IX, and X, and cartilage proteoglycans.¹⁸ The MMP7 gene encodes a protease that breaks down proteoglycans, fibronectin, elastin, and casein.¹⁹

Excluded were women of child-bearing potential or unwilling to use an effective method of birth control; the presence of uncontrolled or serious disease; and any medical or surgical condition that may either interfere with interpretation of the trial results and/or put the subject at significant risk (in the investigator's judgment) if the subject took part in the trial.

TABLE 1.

Investigator's Global Assessment (IGA) Scale Used to Grade the Severity of Acne

Score	Appearance	Description
0	Clear	Residual hyperpigmentation and erythema may be present
1	Almost clear	A few scattered comedones and a few small papules
2	Mild	Some comedones and some papules and pustules, no nodules
3	Moderate	Many comedones, papules, and pustules. One nodule may be present
4	Severe	Covered with comedones, numerous papules and pustules, and a few nodules and cysts may be present
5	Very severe	Highly inflammatory acne covering the face, nodules and cysts present

Severity of Acne

Acne severity was graded at specific time points using the Investigators Global Assessment (IGA) scale (Table 1).²⁰⁻²⁴ The mean (\pm SD) IGA score of all patients before the start of therapy was 1.8 ± 0.2 .

Quality of life was graded by the Dermatology Life Quality Index (DLQI) (Table 2).²⁵⁻²⁷ If two or more questions were not answered, data were not considered in statistical processing. The questionnaire was completed by patients at the beginning of the study (before laser treatment) and at the end of the study. A total index was calculated from the DLQI data; its minimum value corresponded to 0 points and the highest value was 30 points. Thus, a large index value indicated a strong negative impact of the skin condition on the patient's quality of life. The mean (\pm SD) DLQI score before laser treatment was 10.1 ± 1.3 .

Procedure

All patients underwent the combination therapy for 6 months. Patients received systemic isotretinoin at a low dosage (0.2-0.3 mg/kg/day) and facial laser treatment using a 650-microsecond, 1064-nm Nd:YAG laser with a fluence of 21 J/cm² and spot diameter of 6 mm via a collimated beam. A total of 12 laser procedures were performed per subject at 2-week intervals.

Data Analysis

Data were evaluated by descriptive statistics and a t-test was used to test for significant differences using $P=0.05$ as the cut-off value.

RESULTS

All patients completed the study. IGA parameters decreased from 1.8 ± 0.2 (mean \pm SD) initially to 0.5 ± 0.4 at the end of the study, a 72.2% reduction which was significant ($P<0.01$). The DLQI index decreased from 10.1 ± 1.3 initially to 2.8 ± 1.2 , a 72.3% reduction which was significant ($P<0.01$). Inflammatory elements resolved without scarring. Laser treatment was well tolerated, and the treated areas healed without adverse events. Improvement in pre-existing scars was noticeable. Clinical examples are provided in Figures 1-6.

TABLE 2.

The Dermatology Life Quality Index		
Question	Response	Points
How much does itching, pain, burning, soreness of skin bother you?	very much (very frequently)	3
	a lot (frequently)	2
	not much	1
	not at all or difficult to respond	0
How insecure have you felt in everyday life due to your skin condition?	very much (very frequently)	3
	a lot (frequently)	2
	not much	1
	not at all or difficult to respond	0
How much has the condition of your skin interfered with your shopping, household chores?	very much (very frequently)	3
	a lot (frequently)	2
	not much	1
	not at all or difficult to respond	0
How much has your skin condition affected your clothing choices?	very much (very frequently)	3
	a lot (frequently)	2
	not much	1
	not at all or difficult to respond	0
How much has the condition of your skin prevented your contacts with others, active rest?	very much (very frequently)	3
	a lot (frequently)	2
	not much	1
	not at all or difficult to respond	0
How much has your skin condition prevented you from exercising and working out?	very much (very frequently)	3
	a lot (frequently)	2
	not much	1
	not at all or difficult to respond	0
Has your skin condition prevented you from working or studying?	Yes	3
	No	0
Has your skin condition affected your relationships with friends, relatives, partners?	very much (very frequently)	3
	a lot (frequently)	2
	not much	1
	not at all or difficult to respond	0
How badly has your skin condition affected your intimate life?	very much (very frequently)	3
	a lot (frequently)	2
	not much	1
	not at all or difficult to respond	0
How much has the treatment of your disease changed your life (for example, you have lost a lot of time, money, you paid less attention to work, family)?	very much (very frequently)	3
	a lot (frequently)	2
	not much	1
	not at all or difficult to respond	0

FIGURE 1. A 24-year-old male before (left) and after 12 treatments (right) with the 650-microsecond laser at 2-week intervals.

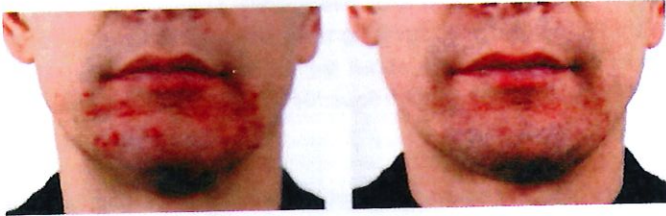

FIGURE 3. A 19-year-old male before (left) and after 12 treatments (right) with the 650-microsecond laser at 2-week intervals.

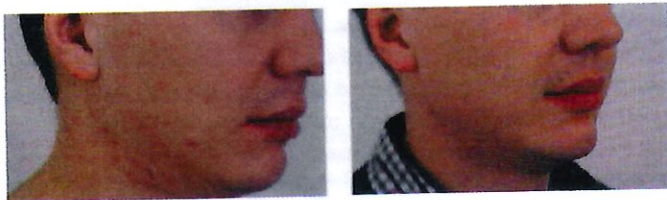

FIGURE 5. A 25-year-old female before (left) and after 12 treatments (right) with the 650-microsecond laser at 2-week intervals.

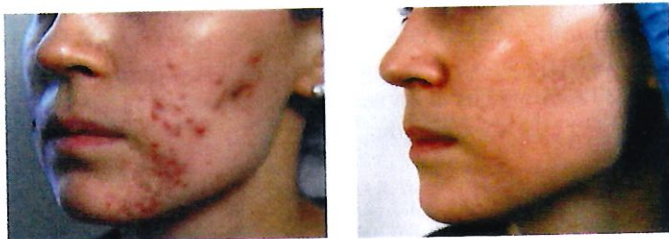

FIGURE 2. A 25-year-old female before (left) and after 12 treatments (right) with the 650-microsecond laser at 2-week intervals.

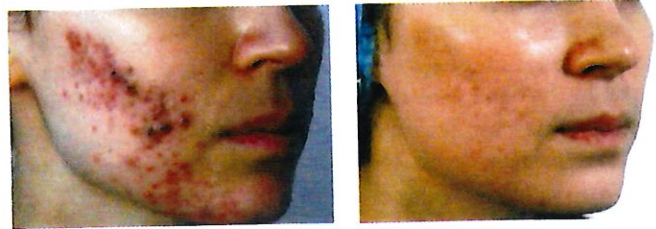

FIGURE 4. A 25-year-old female before (left) and after 12 treatments (right) with the 650-microsecond laser at 2-week intervals.

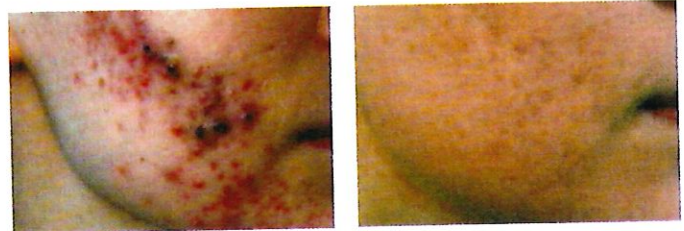
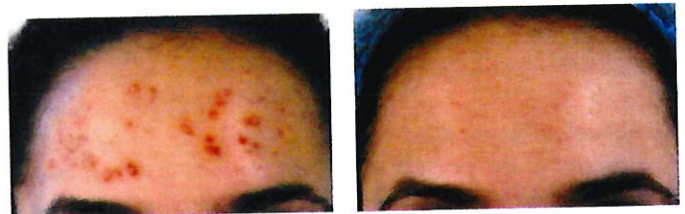


FIGURE 6. A 19-year-old female before (left) and after 12 treatments (right) with the 650-microsecond laser at 2-week intervals.



DISCUSSION

The results show that the 650-microsecond, 1064-nm laser in combination with low-dose isotretinoin is a safe and effective therapy for patients with acne complicated by atrophic scars and genetically prone to formation of post-acne scarring. The combination therapy stimulates the synthesis and reorganization of collagen without excessive tissue heating and patient discomfort.²⁸ Pathological scarring common in acne patients was not observed and, in many patients, improvement in pre-existing scars was apparent.

The advantages of the 650-microsecond Nd: YAG 1064-nm laser for the treatment of acne have been described in detail²⁹⁻³² and will be summarized. This laser permits the user to optimize outcomes by taking advantage of the 650-microsecond pulse duration, which is shorter than the thermal relaxation time of the therapeutic target. This feature minimizes thermal damage

to surrounding tissues, pigmentary changes, scarring, and pain during or after treatment. The long wavelength (1064 nm) and the 650-microsecond pulse duration combine to permit the user to more safely treat darker skin types without skin cooling or numbing.

The pulse duration of conventional 1064-nm lasers is between 5 and 30 milliseconds, much higher than the 700-microsecond thermal relaxation time of skin tissue. With long pulse durations, the target tissue must be cooled continuously to reduce pain during treatment and minimize damage to surrounding tissue. The 650-microsecond laser, with its pulse width less than 700 microseconds, does not require cooling and therefore represents a more viable treatment option, particularly for uneven surfaces such as skin with acne or acne scars.

The 650-microsecond laser also delivers energy in a collimated beam, which allows the physician to vary handpiece-to-skin distance without changing the fluence, thus improving both safety and efficacy during treatment. These features make the 650-microsecond 1064-nm laser safer, more repeatable, and less dependent on operator technique.³² The lack of contact to the skin by the handpiece also makes for a hygienic treatment as a means of avoiding potential transfer of pathogens to the skin that otherwise can happen with the common features of other laser devices that make contact with a handpiece.

Low-dose Isotretinoin

Isotretinoin is FDA-approved for the treatment of severe cases of nodulocystic acne.³³ The recommended dose has been 0.5-1.0 mg/kg/day for 16 to 32 weeks, with a maximum cumulative dose 120 mg/kg.³³⁻³⁶ Adverse effects due to isotretinoin, which include cheilitis, eczema, and tiredness, have been shown to be dose dependent.³⁷ In this 1743-patient study, patients treated with 0.25 mg/kg/day reported cheilitis in 47%, eczema in 7%, and tiredness in 5%, while those treated with 0.75 mg/kg/day experienced these adverse effects in 96%, 16%, and 18%, respectively. The author concluded that isotretinoin was very effective against acne and had a low adverse effect profile at lower doses.

To treat mild to moderate acne, low doses of isotretinoin have been suggested to reduce dose-dependent side effects^{36,38-44} and to reduce costs of treatment.^{38,43} Even for severe acne, lower doses of 0.3 to 0.5 mg/kg/day appear to be as effective as 1 mg/kg/day, but relapse rates are high.^{45,46}

Combination Therapy

The results of the present study are consistent with those of previous studies in which patients with acne or acne scars have undergone laser treatment during or shortly after treatment with low-dose isotretinoin⁴⁷⁻⁵⁰ without serious side effects. Yoon and colleagues⁴⁷ reported better than fair improvement in 35 patients with acne scars after treatment with a 1550-nm Erbium doped fiber laser while taking isotretinoin (10 mg/day). Aggravation of acne scars, hypertrophic scars, or keloids were not observed. In a 20-patient study of patients with facial acne scars,⁴⁸ patients received full-face fractional ablative CO₂ laser treatment while receiving oral isotretinoin or after having completed the systemic treatment within the previous 1 to 3 months. All patients showed normal re-epithelialization without hypertrophic scars or keloids. Saluja and colleagues,⁴⁹ in a 10-patient split-face study, reported normal wound healing after nonablative fractional laser treatment of acne scars within 1 month after patients completed isotretinoin therapy. Xia and coworkers,⁵⁰ in a similar split-face study in patients with moderate to severe acne and undergoing low-dose isotretinoin therapy, reported significant improvement in acne lesions and atrophic boxcar scars without serious complications after three treatments with a nonablative fractional laser.

In their survey of 220 nationally recognized experts in cutaneous laser surgery, Prather and coworkers,⁵¹ with a 42% response rate, found that most respondents reported a low complication rate in patients treated with lasers while taking isotretinoin or within 6 months of completing their therapy. Although respondents reported concern about the risk of poor wound healing and scarring, their most frequently reported concern was the medicolegal risk.

Mysore and colleagues¹² suggest that early studies advocating a 6 to 8-month delay after completion of isotretinoin therapy have limited validity today because these reports had small sample sizes, were case reports, and were published when lasers were in early stages of development. Modern laser devices have improved in safety, precision, and invasiveness. Dermabrasion is rarely performed today and less aggressive procedures such as superficial peels and microdermabrasion have taken hold. These arguments and those described earlier^{10,11} support the view that postponing laser treatments in patients receiving isotretinoin is not necessary, which is consistent with the results of the present study.

Our encouraging results justify additional studies with more patients, different doses of isotretinoin, a longer follow-up time, and the inclusion of a control group.

CONCLUSION

The 650-microsecond, 1064-nm laser in combination with low-dose isotretinoin is a safe and effective therapy for patients with acne complicated by atrophic scars and genetically prone to formation of post-acne scarring.

DISCLOSURES

Dr. Gold is a consultant, performs research, and heads the Medical Advisory Board for Aerolase. The co-authors have nothing to disclose.

REFERENCES

1. Rubenstein R, Roenigk HH Jr, Stegman SJ, Hanke CW. Atypical keloids after dermabrasion of patients taking isotretinoin. *J Am Acad Dermatol.* 1986;15(2 Pt 1):280-285.
2. Zachariae H. Delayed wound healing and keloid formation following argon laser treatment or dermabrasion during isotretinoin treatment. *Br J Dermatol.* 1988;118:703-706.
3. Goihman-Yahr M. Keloid formation induced by isotretinoin therapy (Correspondence). *Int J Dermatol.* 1999;38:228-239.
4. Ginarte M, Peteiro C, Toribio J. Keloid formation induced by isotretinoin therapy. *Int J Dermatol.* 1999;38:228-229.
5. Dogan G. Possible isotretinoin-induced keloids in a patient with Behçet's disease. *Clin Exp Dermatol.* 2006;31:535-537.
6. Wootton CI, Cartwright RP, Manning P, Williams HC. Should isotretinoin be stopped prior to surgery? A critically appraised topic. *Br J Dermatol.* 2014;170:239-244.
7. Guadanhim LR, Gonçalves RG, Bagatin E. Observational retrospective study evaluating the effects of oral isotretinoin in keloids and hypertrophic scars. *Int J Dermatol.* 2016;55:1255-1258.
8. Picosse FR, Yarak S, Cabral NC, Bagatin E. Early chemabrasion for acne scars after treatment with oral isotretinoin. *Dermatol Surg.* 2012;38:1521-1526.
9. Chandrashekar BS, Varsha DV, Vasanth V, et al. Safety of performing invasive

- acne scar treatment and laser hair removal in patients on oral isotretinoin: a retrospective study of 110 patients. *Int J Dermatol*. 2014;53:1281-1285.
10. Spring LK, Krakowski AC, Alam M, et al. Isotretinoin and timing of procedural interventions: a systematic review with consensus recommendations. *JAMA Dermatol*. 2017;153:802-809.
 11. Waldman A, Bolotin D, Arndt KA, et al. ASDS Guidelines Task Force: Consensus recommendations regarding the safety of lasers, dermabrasion, chemical peels, energy devices, and skin surgery during and after isotretinoin use. *Dermatol Surg*. 2017;43:1249-1262.
 12. Mysore V, Omprakash HM, Khatri GN. Isotretinoin and dermatosurgical procedures. *Indian J Dermatol Venereol Leprol*. 2019;85:18-23.
 13. Manturova N, Kruglova L, Stenko, A, Ikonnikova E. Genetic predictors of atrophic acne scars. 24th World Congress of Dermatology. June 10-15, 2019. Milan, Italy. Abstract.
 14. Manturova NE, Talibova AM, Kruglova LS, Stenko AG. Prevention and treatment of post-acne atrophic scars. *The Russian Journal of Clinical Dermatology and Venereology*. 2018;17:85-93.
 15. Gene database <https://www.ncbi.nlm.nih.gov/gene/2099>. Accessed January 18, 2020.
 16. Gene database <https://www.ncbi.nlm.nih.gov/gene/1278>. Accessed January 18, 2020.
 17. Gene database <https://www.ncbi.nlm.nih.gov/gene/4312>. Accessed January 18, 2020.
 18. Gene database <https://www.ncbi.nlm.nih.gov/gene/4314>. Accessed January 18, 2020.
 19. Gene database <https://www.ncbi.nlm.nih.gov/gene/4316>. Accessed January 18, 2020.
 20. Allen BS, Smith JG Jr. Various parameters for grading acne vulgaris. *Arch Dermatol*. 1982;118:23-25.
 21. CDER. *Draft Guidance – Acne Vulgaris: Developing Drugs for Treatment*. Rockville, MD: United States Food and Drug Administration; September 2005.
 22. Thiboutot DM, Weiss J, Bucko A, et al. Adapalene-benzoyl peroxide, a fixed-dose combination for the treatment of acne vulgaris: results of a multicenter, randomized double-blind, controlled study. *J Am Acad Dermatol*. 2007;57:791-799.
 23. Tan JK, Tang J, Fung K, et al. Development and validation of a comprehensive acne severity scale. *J Cutan Med Surg*. 2007;11:211-216.
 24. Dréno B, Poli F, Pawin H, et al. Development and evaluation of a Global Acne Severity Scale (GEA Scale) suitable for France and Europe. *J Eur Acad Dermatol Venereol*. 2011;25:43-48.
 25. Finlay AY, Khan GK. Dermatology Life Quality Index (DLQI): a simple practical measure for routine clinical use. *Clin Exp Dermatol*. 1994;19:210-216.
 26. Basra MK, Fenech R, Gatt RM, et al. The Dermatology Life Quality Index 1994-2007: a comprehensive review of validation data and clinical results. *Br J Dermatol*. 2008; 159:997-1035.
 27. Hongbo Y, Thomas CL, Harrison MA, et al. Translating the science of quality of life into practice: What do dermatology life quality index scores mean? *J Invest Dermatol*. 2005;125:659-664.
 28. Pinski KS, Mannausa K. Comprehensive non-ablative laser skin rejuvenation using a 650 microsecond pulsed Nd:YAG 1064nm laser. Presented at the 37th annual conference of the American Society for Laser Medicine & Surgery, San Diego, CA, April 5-9, 2017. Abstract.
 29. Khatri K, Geraskova N. Clinical Study: Treatment of moderate to severe acne with a 650-microsecond pulsed Nd: YAG 1064-nm laser using high fluences and stacked pulses at a low repetition rate. Paper presented at: American Society for Laser Medicine and Surgery 2014 Annual Conference; April 2-6, 2014; Phoenix, AZ.
 30. Gold MH, Goldberg DJ, Nestor MS. Current treatments of acne: medications, lights, lasers, and a novel 650-µs 1064-nm Nd: YAG laser. *J Cosmet Dermatol*. 2017;16:303-318.
 31. Roberts WE, Henry M, Burgess C, et al. Laser treatment of skin of color for medical and aesthetic uses with a new 650-microsecond Nd:YAG 1064nm laser. *J Drugs Dermatol*. 2019;18:s135-s137.
 32. Goldberg, David J. 650 usec, 1064nm Nd:YAG laser treatment of acne: a double-blind randomized control study. Paper presented at: International Master Course on Aging Skin (IMCAS) 2020 Annual Conference. January 28-30. Paris, France.
 33. Cunliffe WJ, van de Kerkhof PC, Caputo R, et al. Roaccutane treatment guidelines: results of an international survey. *Dermatology*. 1997;194:351-357.
 34. Pochi PE, Shalita AR, Strauss JS, et al. Report of the Consensus Conference on Acne Classification. Washington, D.C., March 24 and 25, 1990. *J Am Acad Dermatol*. 1991;24:495-500.
 35. Dréno B, Bodokh I, Chivot M, et al. ECLA grading: a system of acne classification for every day dermatological practice. *Ann Dermatol Venereol*. 1999;126:136-141.
 36. Sardana K, Garg VK. Efficacy of low-dose isotretinoin in acne vulgaris. *Indian J Dermatol Venereol Leprol*. 2010;76:7-13.
 37. Rademaker M. Adverse effects of isotretinoin: A retrospective review of 1743 patients started on isotretinoin. *Australas J Dermatol*. 2010;51:248-253.
 38. Goulden V, Clark SM, McGeown C, Cunliffe WJ. Treatment of acne with intermittent isotretinoin. *Br J Dermatol*. 1997;137:106-108.
 39. Seukeran DC, Cunliffe WJ. Acne vulgaris in the elderly: the response to low-dose isotretinoin. *Br J Dermatol*. 1998;139:99-101.
 40. Palmer RA, Sidhu S, Goodwin PG. 'Microdose' isotretinoin. *Br J Dermatol*. 2000;143:205-206.
 41. Hermes B, Praetel C, Henz BM. Medium dose isotretinoin for the treatment of acne. *J Eur Acad Dermatol Venereol*. 1998;11:117-121.
 42. Mandekou-Lefaki I, Delli F, Teknetzis A, et al. Low-dose schema of isotretinoin in acne vulgaris. *Int J Clin Pharmacol Res*. 2003;23:41-46.
 43. Amichai B, Shemer A, Grunwald MH. Low-dose isotretinoin in the treatment of acne vulgaris. *J Am Acad Dermatol*. 2006;54:644-646.
 44. Lee JW, Yoo KH, Park KY, et al. Effectiveness of conventional, low-dose and intermittent oral isotretinoin in the treatment of acne: a randomized, controlled comparative study. *Br J Dermatol*. 2011;164:1369-1375.
 45. Bellostta M, Vignini M, Miori L, Rabbiosi G. Low-dose isotretinoin in severe acne. *Int J Tissue React*. 1987;9:443-446.
 46. Sardana K, Sehgal VN. Retinoids: fascinating up-and-coming scenario. *J Dermatol*. 2003;30:355-380.
 47. Yoon JH, Park EJ, Kwon IH, et al. Concomitant use of an infrared fractional laser with low-dose isotretinoin for the treatment of acne and acne scars. *J Dermatolog Treat*. 2014;25:142-146.
 48. Kim HW, Chang SE, Kim JE, et al. The safe delivery of fractional ablative carbon dioxide laser treatment for acne scars in Asian patients receiving oral isotretinoin. *Dermatol Surg*. 2014;40:1361-1366.
 49. Saluja SS, Walker ML, Summers EM, et al. Safety of non-ablative fractional laser for acne scars within 1 month after treatment with oral isotretinoin: A randomized split-face controlled trial. *Lasers Surg Med*. 2017;49:886-890.
 50. Xia J, Hu G, Hu D, et al. Concomitant use of 1,550-nm nonablative fractional laser with low-dose isotretinoin for the treatment of acne vulgaris in asian patients: a randomized split-face controlled study. *Dermatol Surg*. 2018;44:1201-1208.
 51. Prather HB, Alam M, Poon E, et al. Laser safety in isotretinoin use: a survey of expert opinion and practice. *Dermatol Surg*. 2017;43:357-363.

AUTHOR CORRESPONDENCE

Michael H. Gold MD

E-mail:..... drgold@goldskincare.com